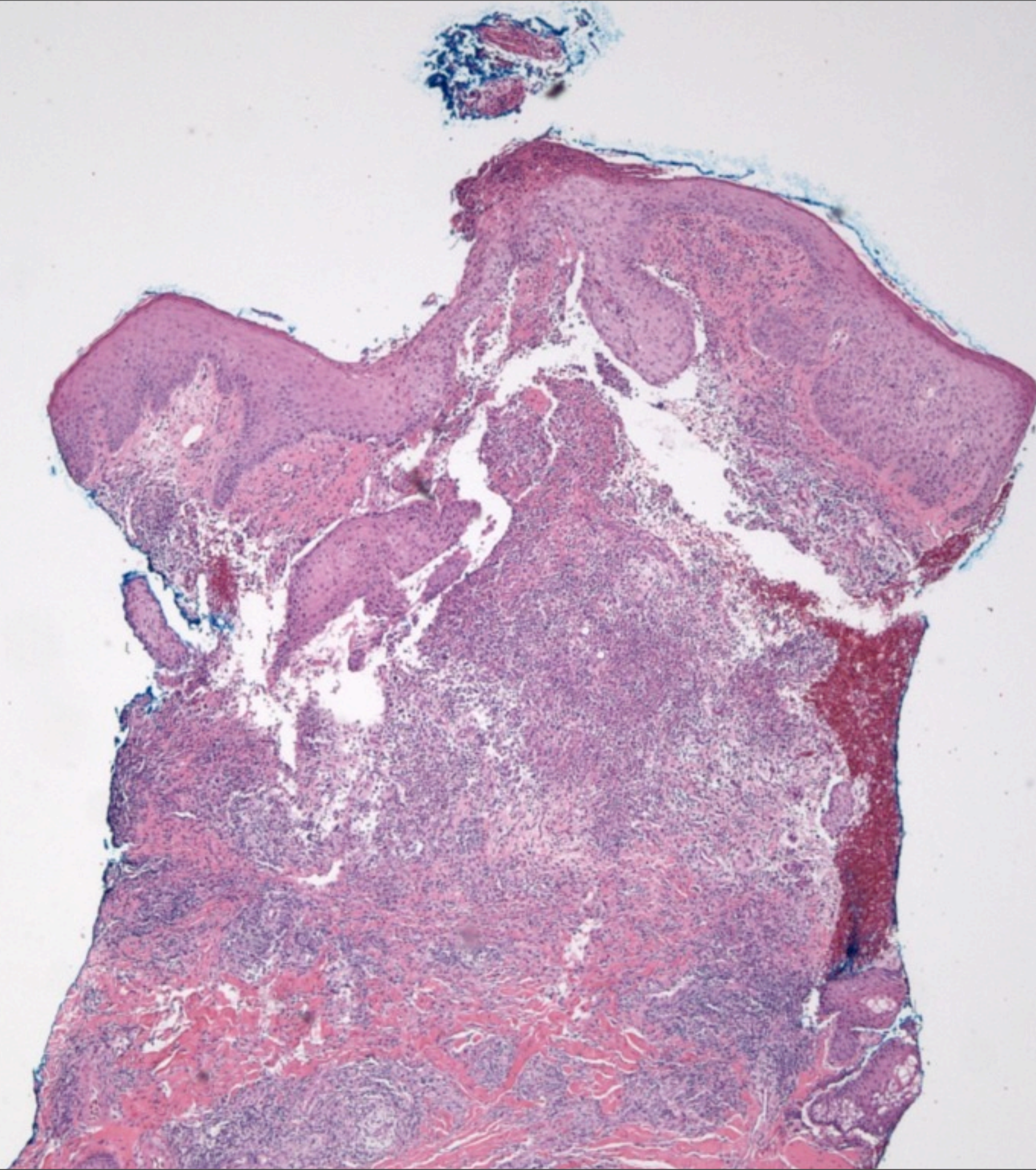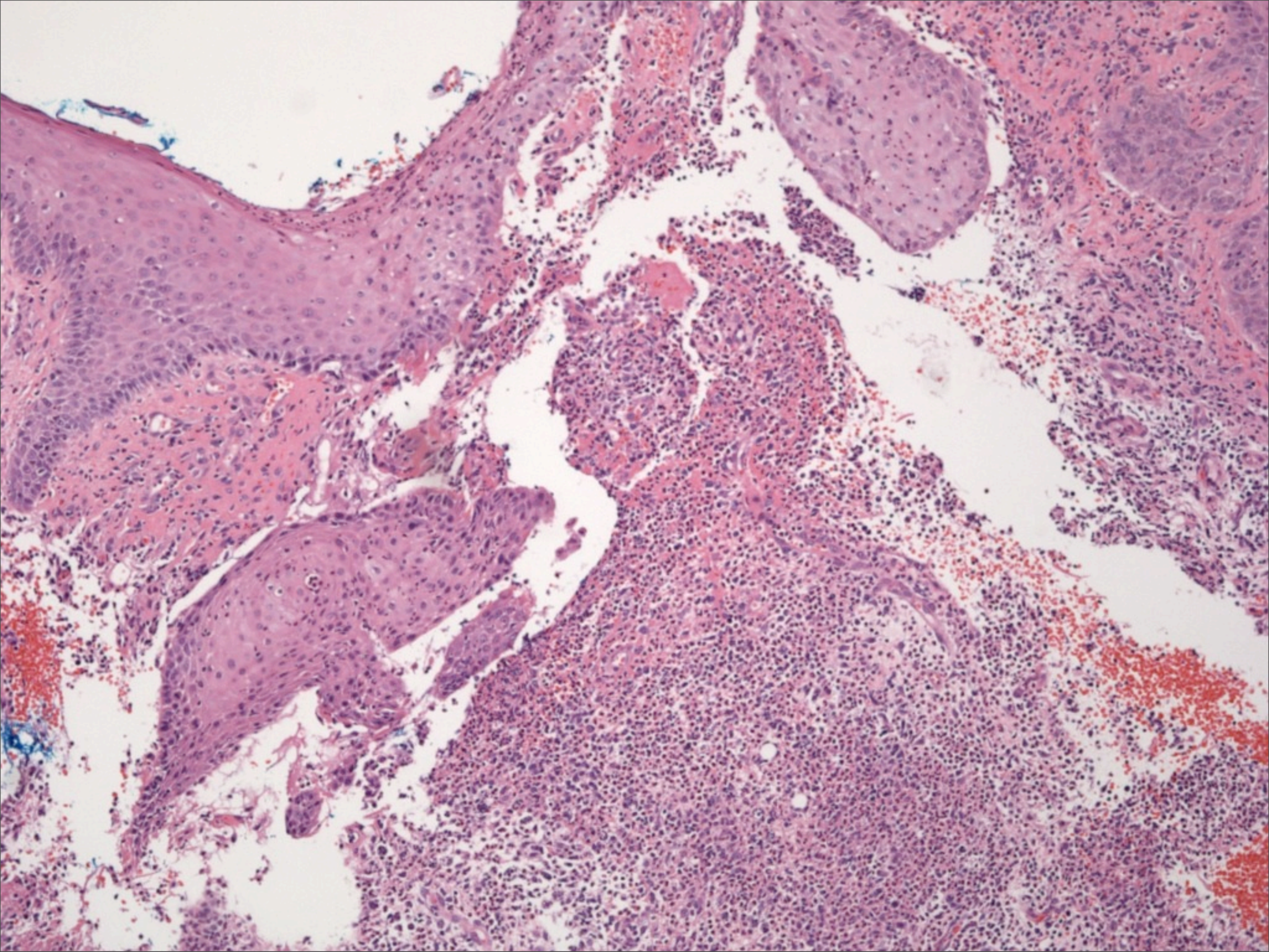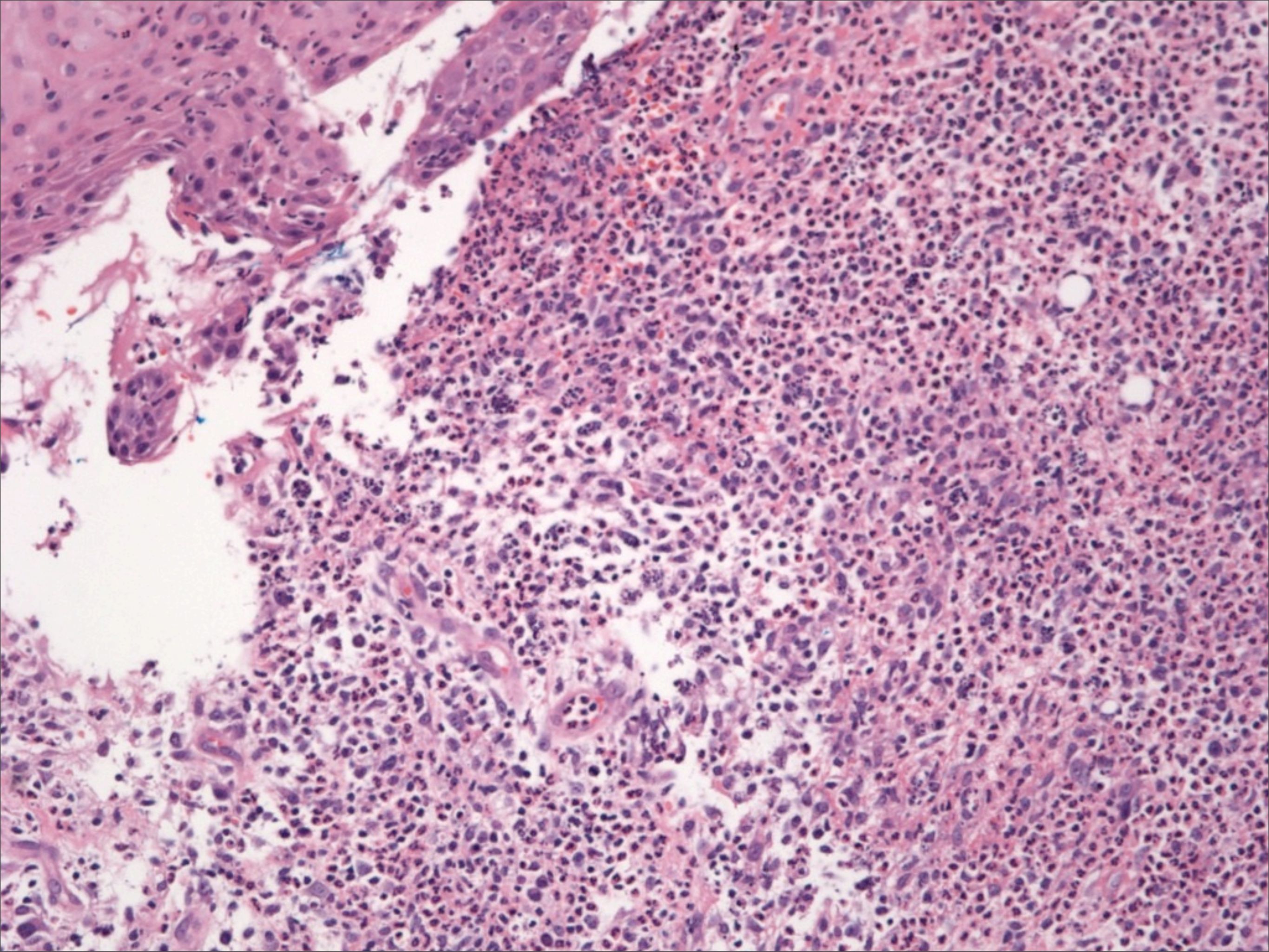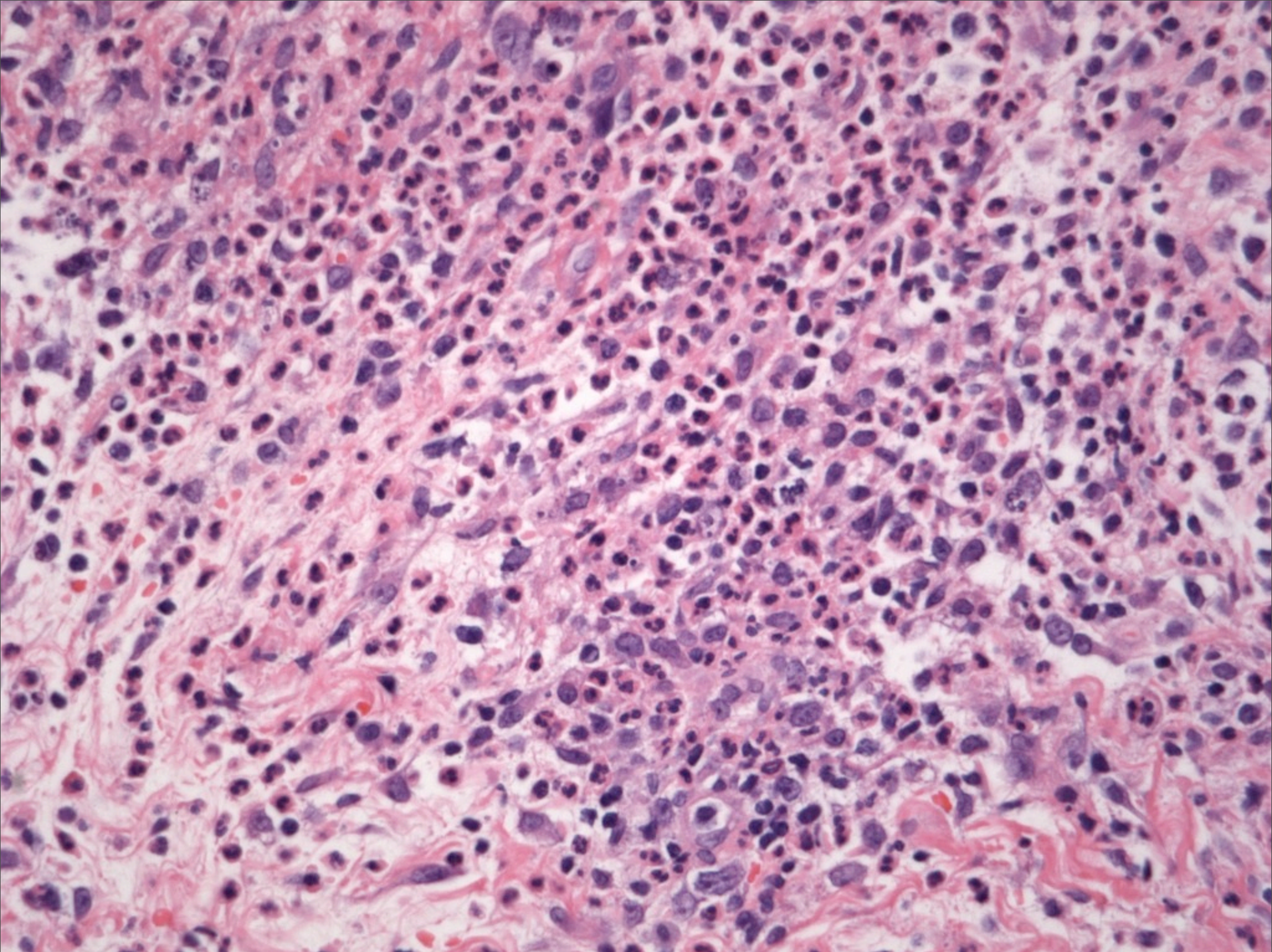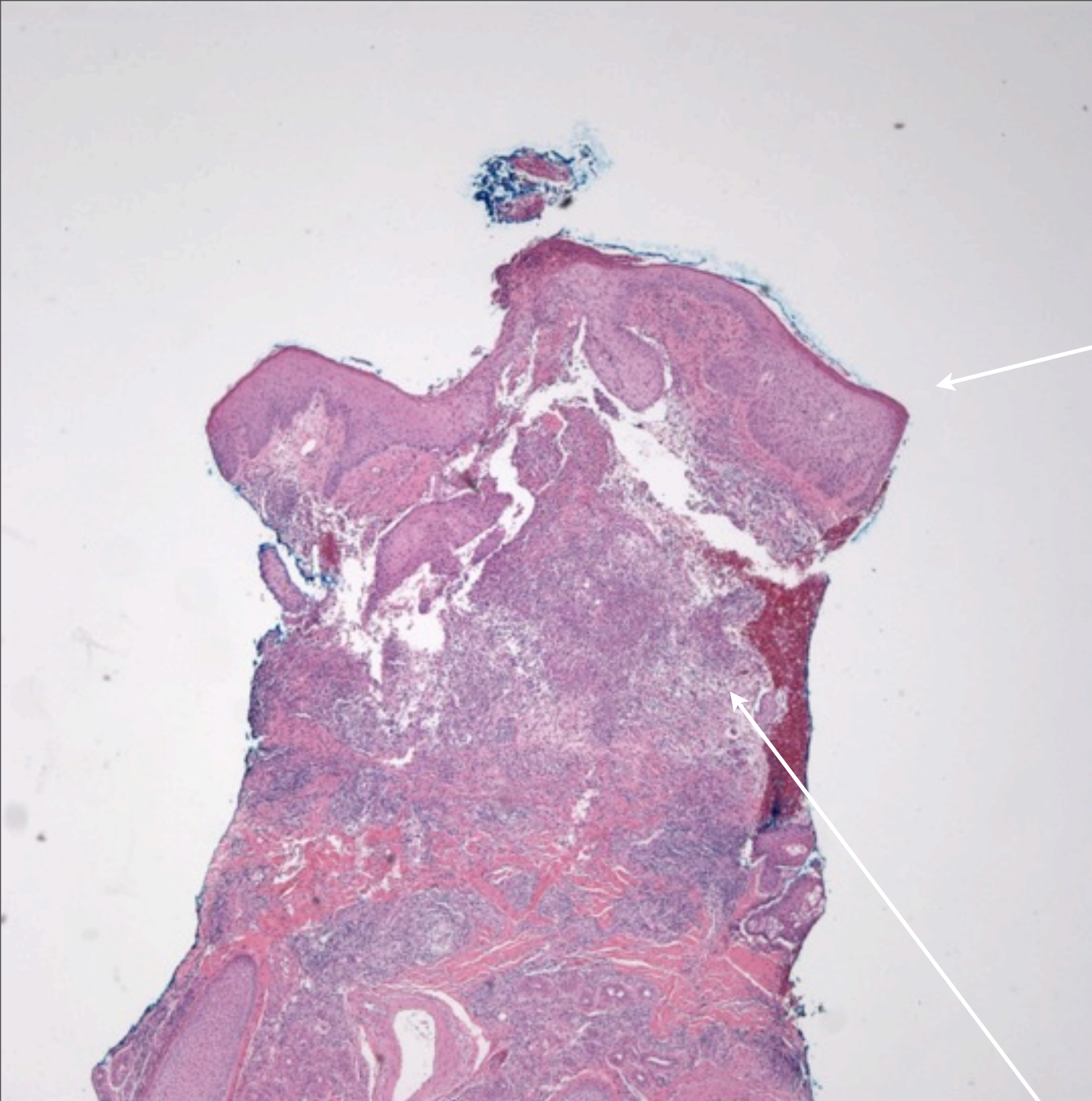


Dissecting Cellulitis of the Scalp



Scalp location

Diffuse neutrophilic infiltrate

Rule out infection